

# Takayasu Arteritis: An Overview

Açucena de Oliveira Borges<sup>1</sup>, Gustavo Almeida Linhares<sup>1</sup>, Leticia Góes Pereira<sup>1</sup>, Rafaela de Moraes Fernandes<sup>1</sup>, Yarla Resende Oliveira<sup>1</sup>, Laura Gomes Lima<sup>2</sup> and Eriston Vieira Gomes<sup>1,3\*</sup>

<sup>1</sup>Morgana Potrich College, FAMP, Medical School, Mineiros, GO, Brazil

<sup>2</sup>University of Rio Verde, UniRV, Medical School, Rio Verde, GO, Brazil

<sup>3</sup>Ribeirao Preto Medical School, FMRP, University of Sao Paulo, USP, Ribeirao Preto, SP, Brazil

## Abstract

Takayasu arteritis is a chronic vasculitis (inflammation of the blood vessel wall) that affects the largest artery in the human body, the aorta, and its main branches. It is a disease which currently does not have a definitive cure and is of idiopathic aetiology. It predominantly affects women (80 to 90% of the affected people are female), aged 10 to 40 years, with a higher prevalence in Asian countries. Its symptoms start from simple systemic manifestations and may lead to serious complications in vital organs, such as congestive heart failure, stroke, and even death. As this is a rare disease, it is essential to be attentive to the minimum signs of its pathology and seeking an early diagnosis, consequently reducing the chance of mortality. This review aims to describe the symptoms of this pathology. The diagnostic methods present the main therapeutic approach and highlight the importance of an early diagnosis for the reduction of the complications caused by this health condition.

**Keywords:** Vasculitis • Takayasu arteritis • Chronic inflammation • Blood vessels • Cardiovascular problems • Aorta artery • Heart • Ischemia

**Abbreviations:** AT: Takayasu Arteritis; HLA: Human Leukocyte Antigen; US: Doppler Ultrasound; PET: Positron Emission Tomography; CTA: Computed Tomography Angiography; MRA: Magnetic Resonance Angiography; DAS: Digital Angiography Subtraction; IS: Immuno Suppressants.

## Introduction

Takayasu Arteritis (TA) is characterised as a rare and systemic vasculitis, which causes chronic granulomatous inflammation mainly in the aorta and its branches, the largest and main blood vessels in the human body. The name 'Takayasu' is due to the first report of the disease by Dr. Mikito Takayasu in 1908 at a meeting of the Japanese Society of Ophthalmology [1]. Its origin is unknown and its incidence is higher in females and young people, and is more common in Asia [2]. Consequently, TA may lead to the narrowing or blockage of large vessels, making it impossible for the affected arteries to irrigate the tissues, resulting in protuberances such as aneurysms [3]. This vasculitis may present greater risks for pregnant women, as it increases the chances of cardiovascular and brain problems, increasing the rates of hypertension, low birth rate, and perinatal mortality [4]. Therefore, considering that TA can cause serious disorders in the body and consequently accumulate damage that can lead to high mortality rates [5], it is essential to understand the clinical signs and have methods that favour an early diagnosis (Figure1), consequently reducing complications and deaths caused by this vascular disease.

## Methods

In this literature review study on TA, the criteria were as follows: Articles published in English, between 2016 and 2020, using the databases Google Scholar, Scielo and PubMed, through descriptors in health science, such as Vasculitis, and Takayasu arteritis.

## Discussion

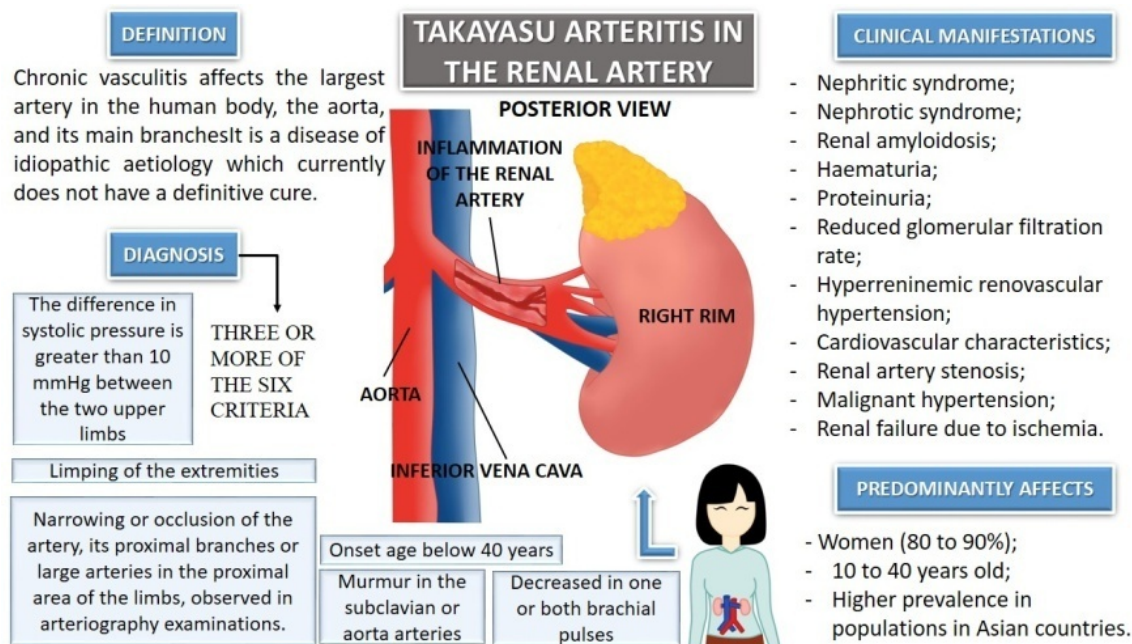
### Aetiology

The Aetiology of TA is idiopathic, with a higher prevalence in women [5]. Some genetic factors are related to its pathogenesis [6]. Human leukocyte antigen (HLA) has different associations according to ethnic origins, such as HLA-B52 in Japanese, probably defining a worse prognosis for this pathology [5]. The KDM4C gene was identified as a common risk for various types of vasculitis, and some genes such as PCSK5, LILRA3, PPM1G/NRBPP1, and PTK2B may have direct associations with TA [6]. Another aspect is the contribution of infectious agents as adjuvants to the pathogenesis of TA since, in the presence of a triggering factor, an immune response mediated by cells that are linked to inflammatory processes is generated [6].

\*Corresponding author: Eriston Vieira Gomes, Department of Biofunctional, Morgana Potrich College, 2 st, Mundinho sector, Mineiros, GO, Brazil, Tel: +55 64999255005; E-mail: eristongomes@hotmail.com

**Copyright:** © 2020 Borges AO, et al. This is an open-access article distributed under the terms of the creative commons attribution license which permits unrestricted use, distribution and reproduction in any medium, provided the original author and source are credited.

**Received:** May 29, 2020; **Accepted:** June 12, 2020; **Published:** June 19, 2020



**Figure 1.** Key features of renal Takayasu arteritis. Left: Definition and main diagnostic criteria, Right: Main clinical manifestations signals and aetiology.

## Clinical features and complications

TA can be asymptomatic, making its early diagnosis difficult because of the small number of people who seek adequate medical care. In countries like Norway and Sweden, there has been an increase in cases due to the immigration of people from Asia and Africa in recent years [2]. The clinical manifestations of TA can be classified in different ways and are usually divided into two stages, early and late, with a three-phase pattern. The first stage ranges for weeks to months, while the second for months to years [5]. The first phase is characterized by inflammatory activity, with systemic and non-specific symptoms such as fever, headache, malaise, weight loss, fatigue, vomiting, and musculoskeletal symptoms [5,7]. The second phase is characterized by inflammation in the great arteries causing specific pains (e.g., carotid-type cardiovascular) [6]. The third phase represents the late phase, which already has a decrease or absence of pulse and symptoms secondary to arterial occlusion [7]. The involvement of different arteries causes different manifestations that possibly evolve to neurological complications (severe headaches, stroke), cutaneous (livedo reticular, purple) cardiovascular (systemic arterial hypertension, precordial pain), gastrointestinal (acute abdominal pain or chronic, vomiting) ocular (abnormalities in the retina, such as tortuosity and dilation of the veins), renal (proteinuria, haematuria), and pulmonary (cough and dyspnea). For a review, see reference [5].

## Diagnose

In men affected by vasculitis, inflammation can compromise the abdominal aorta and its branches, differentiating from women that occur in greater proportion in the thoracic aorta and its branches. The American College of Rheumatology (<https://www.rheumatology.org>) established six diagnostic criteria to define TA (i-onset age below 40 years; ii-limping of the extremities; iii-decreased in one or both brachial pulses; iv-the difference in systolic pressure greater than 10 mmHg between the two upper limbs; v-murmur in the subclavian or

aortic arteries; and vi-narrowing or occlusion of the artery, its proximal branches or large arteries in the proximal area of the limbs observed in arteriography exams). To establish the diagnosis, three or more of the aforementioned criteria are required [4,8,9]. Diagnosis and monitoring of TA are provided by methods such as Doppler ultrasound (US), positron emission tomography (PET), computed tomography angiography (CTA), magnetic resonance angiography (MRA), and angiography by the technique of digital subtraction (DAS). The US shows the morphology of the vessels and edema in their wall detects thrombosis and aneurysms but is limited by being restricted to vessels close to the body surface, such as the carotid and axillary arteries [5,9,10]. PET combines the measurement of the metabolic activity of the arterial wall with laminography, providing information on the degree of disease activity and detecting inflammation; However, it provides poor details on anatomy [9]. The CTA provides the diagnosis in the initial phase of the disease, as it allows assessment of the wall thickness, translation, and anatomical details in the 3D reconstruction images [5]. MRA detects anatomical abnormalities in the walls of vessels and surrounding tissues, such as thickness, edema, and contrast enhancement, assesses inflammation, and discriminates between active and non-active arterial lesions [9]. Finally, DSA evaluates the arterial tree in patients with suspected or confirmed TA and help in better evaluation of the vessel lumen [5]. No specific laboratory tests or biomarkers available for TA activity have yet been established [5,8].

## Treatment

The main goal of therapy for TA is to prevent the progression of arterial lesions since prognosis of the disease is closely linked to this factor, so that delays or failures in the diagnosis are potentially fatal [8,9]. Adequate management includes primarily defining the levels of arterial involvement to follow proper management in therapeutic conduct. Initially, treatment is aimed at suppressing vascular and systemic inflammation. In the active phase, the aim is to stabilise the patient's condition, preferably using drugs [6]. Immuno suppressants (IS) and second-line corticosteroids are generally used in this initial treatment and can be prescribed in combination or individually. Glucocorticoids at a dose of 1 to 2 mg/kg/day for 1 to 3 months, with a gradual reduction after 30 days and IS are usually the first option. The standard initial corticosteroid is prednisolone, and the IS are methotrexate, azathioprine, and mycophenolate mofetil, in that order of preference. For more persistent TA cases, biomolecules can be added to the therapy, including tumour necrosis factor inhibitors, tocilizumab, rituximab, and abatacept [4,6]. Surgical and endovascular approaches are reserved for the treatment of refractory cases with arterial occlusion or cases of severe aneurysms. The choice between one and the other is made in part by the nature and location of the injury. Although angiography is a less invasive procedure, it offers less time for vascular permeability compared to open surgery [11]. However, the scientific evidence to define the best treatment for TA is still insufficient due to the lack of reliable standardised measures of the results [9].

## Author Contribution

All authors contributed equally to the production of this article.

## Conclusion

Although as a low-incidence disease, TA is a condition that requires further studies, considering the initial systemic and non-specific manifestations that lead to late diagnosis and inefficient treatment. Considering that TA has been reported for more than a century, its aetiology still being unknown; consequently, it is necessary to treat its symptoms, with generally unsatisfactory results, since there is still no definitive cure. The available treatments potentiate the inhibition of progress for greater morbidities; however, the longer the diagnosis, the worse the prognosis. Thus, to offer better therapy to patients with this vasculitis, further studies must be carried out to develop more specific diagnostic methods capable of identifying the disease at an early stage and thus developing the best therapy to manage it, aiming to offer better quality of life for patients with this dangerous and frightening illness.

## References

1. Paul, Renauer, and Amr H, Sawalha. "The genetics of Takayasu arteritis". *Presse Med* 46(2017):e179-e187.
2. Seyahi, Emire. "Takayasu arteritis: an update". *Curr Opin Rheumatol* 29(2017):51-56.
3. Serra, Raffaele, Lucia, Butrico, Francesco, Fugetto, and Maria D, Chibireva, et al. "Updates in pathophysiology, diagnosis and management of Takayasu arteritis". *Ann Vasc Surg* 35(2016):210-225.
4. Nara T, Braga, Adriana B, Carneiro, Kathia L, Zuntini, and Flavio B, Araújo, et al. "Takayasu arteritis: Differential diagnosis in a teenager with severe acute kidney injury-a case report". *J Bras Nefrol* 41(2019):564-569.
5. A G Russo, Ricardo, Katsicas, and María M. "Takayasu Arteritis". *Front Pediatr* 6(2018):265.
6. Keser, Gokhan, Aksu Kenan, and Haner, DİRESKENELİ. "Takayasu arteritis: an update". *Turk J Med Sci* 48(2018):681-697.
7. Sueyoshi, Eijun, Ichiro, Sakamoto, and UetaniMasataka. "MRI of Takayasu's arteritis: typical appearances and complications". *AJR Am J Roentgenol* 186(2006):W569-W575.
8. Bonilla, Sofia R, Rossi, Cristina G, and Montero, Jairo Arce. "Arteritis de Takayasu". *Revista Clínica de la Escuela de Medicina UCR-HSJD* 9(2019): 49-52.
9. Nakagomi, Daiki, and Jayne, David. "Outcome assessment in Takayasu arteritis". *Rheumatology* 55(2016):1159-1171.
10. An, Xuanqi, Han, Yechen, Zhang, Bingqing, and Qiao, Lin, et al. "Takayasu arteritis presented with acute heart failure: case report and review of literature". *ESC Heart Fail* 4(2017):649-654.
11. Mason, Justin C. "Surgical intervention and its role in Takayasu arteritis". *Best Pract Research Clin Rheumatol* 32(2018):112-124.

**How to cite this article:** Borges, Acucena de Oliveira, Linhares, Gustavo Almeida, Pereira, Leticia Goes, and Fernandes, Rafaela de Moraes et al. "Takayasu Arteritis: An Overview". *J Vasc* 6 (2020) doi:10.37421/JOV.2020.6.132